

Navicular Syndrome

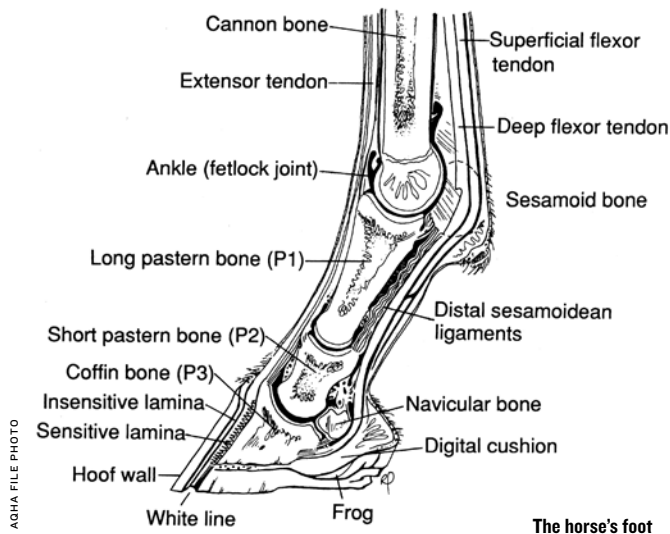
The latest information on navicular issues.

By Dr. Patrick First

NAVICULAR SYNDROME IS A BROAD TERM THAT IS USED TO describe soreness or damage to the navicular bone and its surrounding structures in the equine foot. It has been labeled with a variety of titles including navicular disease, palmar foot pain, navicular syndrome and heel sore. No matter how you label it, damage to the navicular bone and its surrounding structures is a common cause of lameness that has great potential for a successful outcome with appropriate management.

The equine foot is a complex unit with many moving parts, designed to provide support to the limb and properly disperse concussion from the ground. The heel of the horse is a vital component in the overall soundness of the animal. Damage to any one of the structures surrounding the navicular bone or to the navicular bone itself can cause lameness. These structures include the navicular bone, navicular bursa, coffin bone, impar ligament, suspensory ligament of the navicular, deep digital flexor tendon, digital cushion, frog and heel bulbs.

If your horse is diagnosed with navicular syndrome, don't fret. There are many treatment options, and with the help of your veterinarian and farrier, the syndrome can be appropriately managed.



Diagnosis

THE TYPICAL PRESENTATION FOR A HORSE WITH NAVICULAR SYNDROME is an intermittent lameness in the front limbs that progresses over time, but tends to improve with rest during the off season. In many cases, lameness will be most evident in training for the track when the horse is being worked at its hardest.

You may only notice the occasional slight head bob, and then talk yourself out of a possible lameness due to its brevity. The horse will often have a short stabbing stride at the trot and may point a foot when standing, avoiding heel contact with the ground. Many horses will have the classic long-toe/low-heel that crushes the soft-tissue structures in the back of the foot; while others will have a tall heel and a snubbed toe from placing each step toe first.

Navicular syndrome is most prevalent in Quarter Horses, Thoroughbreds, Paints and warmbloods with the average age being 7-14 years old.

Once suspicion of lameness arises, a workup should be performed by your veterinarian. This will involve watching the horse move, joint flexions and hoof testing. Some navicular horses will be painful to hoof testers over the heel region when they are applied from frog to hoof wall and from quarter to quarter.

Next, a palmar digital nerve block will likely be performed. This block will numb the back one-third to two-thirds of the foot. The navicular bone and its surrounding structures fall within this area. Once the block takes effect, the horse will be examined again at the trot for an improvement in soundness. If substantial improvement is noted, the lameness has been located to this area of the foot and imaging can then be performed.

Interpretation of imaging should be supported by findings from the lameness examination. In most cases, radiographs (X-rays) will be taken of the navicular bone to determine if there are any degenerative changes seen (evidence of arthritis, navicular cysts or proliferation of bone). Some horses will show little to no lameness, but have degenerative changes of the navicular bone. Conversely, some horses will be lame with no evidence of navicular changes on X-ray.

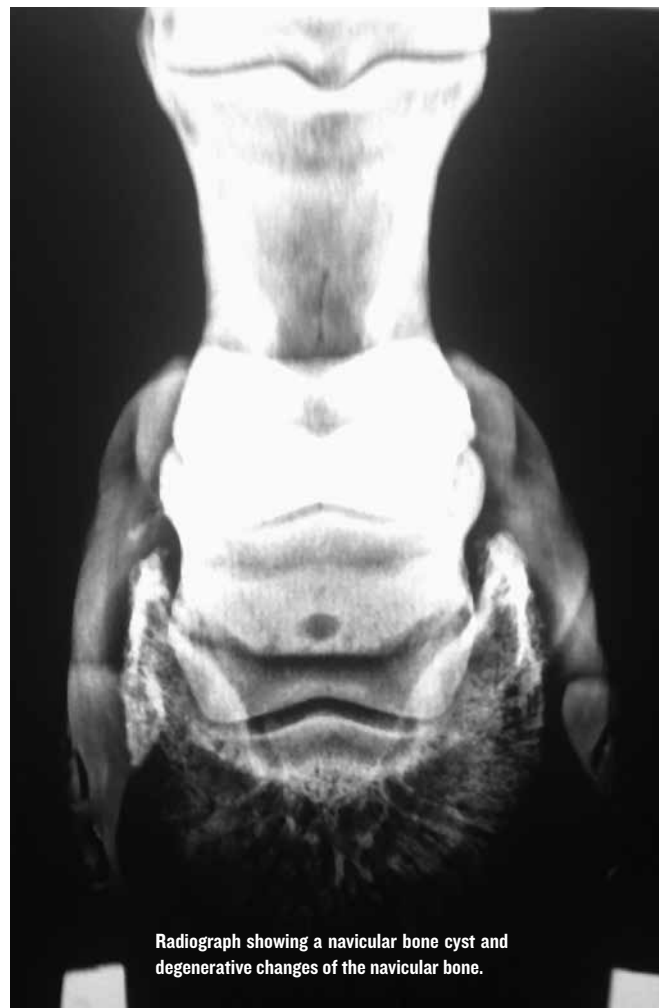
This is where advanced imaging like magnetic resonance imaging (MRI) comes into play. MRI identifies soft-tissue support structures around the navicular bone that can become injured which cannot be seen with X-rays.

The downside to an MRI is the expense (typically \$1,500-\$2,500) and also a potential anesthetic risk. Most facilities that offer MRIs have to place horses under general anesthesia for this procedure. However, there are some facilities that have standing MRI units.

Once your veterinarian has found a diagnosis with imaging, an appropriate treatment plan that is suitable for owner and patient can be developed.

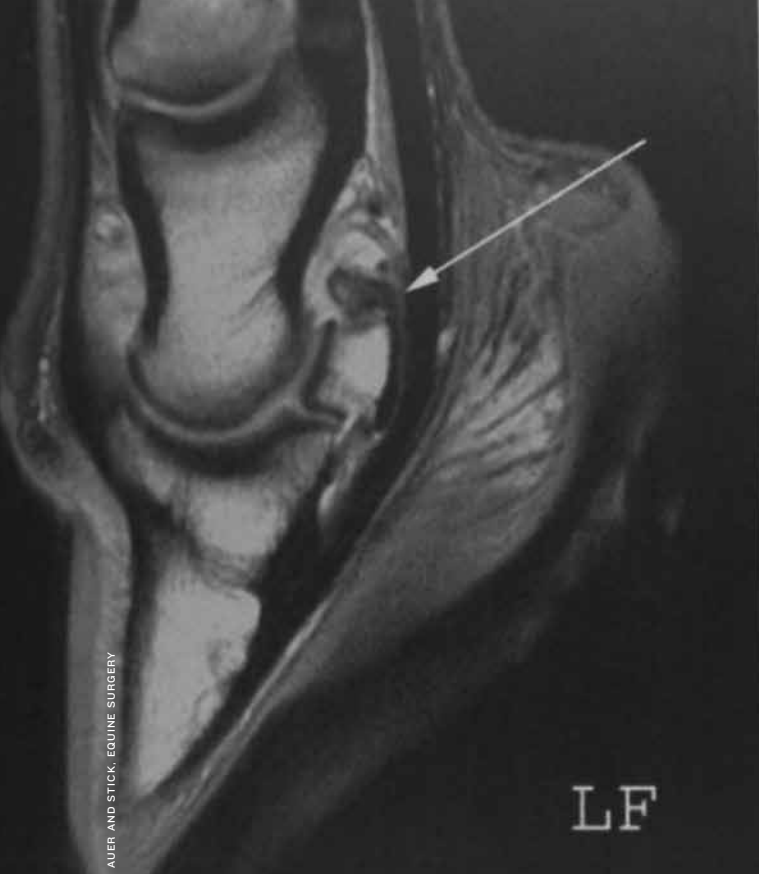Management

THE FOUNDATION FOR MANAGEMENT OF NAVICULAR IS TO BALANCE the foot with corrective shoeing and rest. Other therapeutics that can be instituted include giving non-steroidal anti-inflammatory drugs (NSAIDs), steroid injections into the coffin joint or navicular bursa, shockwave therapy, bisphosphonate drugs and surgery. In the past few years, several new medications have become available for veterinarians to use when treating navicular. Treatment should be based on alleviating clinical signs, relieving stress on the navicular bone and surrounding structures, and slowing the degenerative process.

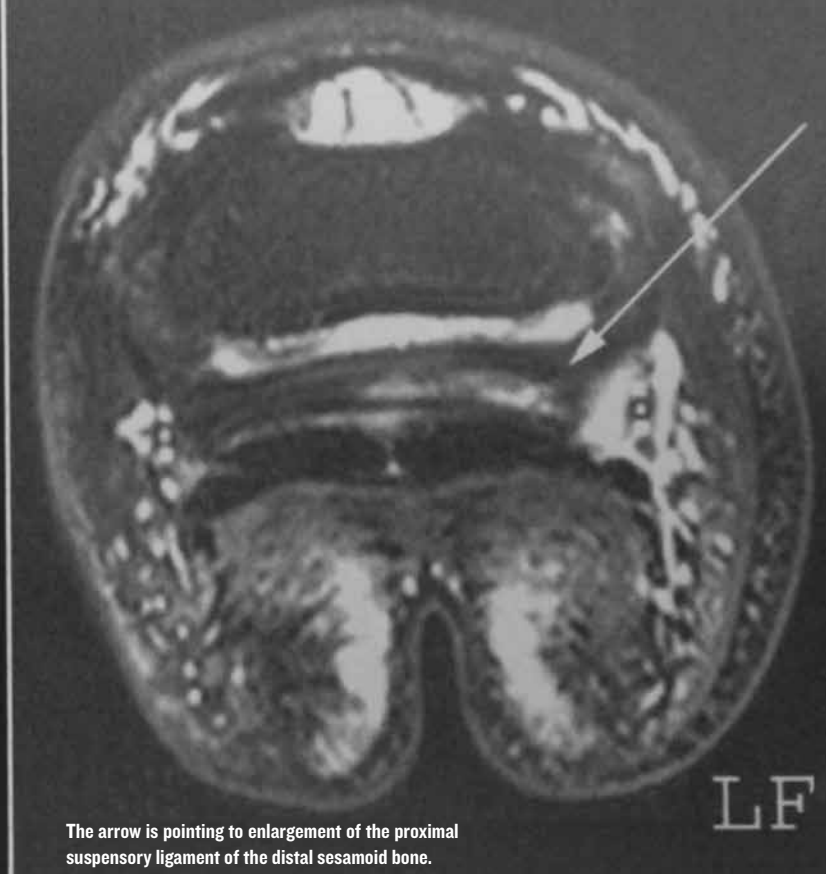

Radiograph showing a navicular bone cyst and degenerative changes of the navicular bone.

COURTESY WILLIAM SCHUB



AUER AND STICK, EQUINE SURGERY



The arrow is pointing to enlargement of the proximal suspensory ligament of the distal sesamoid bone.

Shoeing

CORRECTIVE SHOEING AND BALANCING OF THE HOOF SHOULD BE based on X-rays. Proper hoof balance involves assessment of the hoof from all angles and measuring any deviations from normal. Many navicular horses are “broken back,” and have a hoof-pastern axis that is not in line, which places excess stress on the navicular bone. The navicular bone should act as a pulley system for the deep digital flexor tendon. With a broken-back hoof pastern axis, the pulley will receive a greater load.

Many theories exist on how to appropriately shoe the navicular horse, with differing opinions among many veterinarians and farriers. With the goal being to reduce load on the navicular bone, a wedge shoe is frequently used to correct the hoof pastern axis and restore a more correct angle. In addition, a deformable pad to support the soft tissue structures of the heel can be used. Ease of breakover can be improved by shortening and rolling the toe. Along with rest, corrective shoeing is the most important aspect in the treatment of navicular syndrome. If a foot remains unbalanced, the cycle of pain and inflammation will only continue, even with the addition of medications.

Rest

UNFORTUNATELY, RESTING A PERFORMANCE HORSE IS OFTEN overlooked due to upcoming competitions. Rest or controlled exercise is a key component to rehabilitating the navicular horse. This is especially true with injuries to the soft-tissue structures surrounding the navicular bone. Injuries to ligaments or tendons typically require four to six months of rest or longer.

However, in most situations, a period of three to four weeks of rest is necessary while medical management and corrective shoeing is being started. This allows time for inflammation to subside, and shoeing measures to take effect.

Medications

A WIDE VARIETY OF NSAIDS CAN BE USED IN THE TREATMENT OF navicular syndrome. Many veterinarians will prescribe bute (phenylbutazone) for acute pain, and then decrease the dosing as inflammation and clinical signs diminish. However, long-term use of bute is associated with gastrointestinal ulcers, especially at high doses.

Another NSAID that is frequently used by veterinarians is firocoxib, which can be given over a longer period of time with less risk of gastrointestinal ulceration. No matter what NSAID is used, an appropriate dosing schedule should be formulated with your veterinarian. Many owners will give an NSAID before riding or for their next event to avoid excessive dosing. Pain management is a significant concern in the treatment of navicular syndrome, and the appropriate NSAID and dosing schedule should be carefully considered.

Isoxuprine is another medication in the veterinarian’s arsenal to treat navicular syndrome. The efficacy of the drug is controversial, but many practitioners believe it to be effective. It is thought to act as a vasodilator to improve perfusion to the navicular bone. Due to the complexity of navicular syndrome, and the many different structures that can become injured in the foot, it is thought that Isoxuprine may help a certain subset of horses while not benefiting all.

Within the past few years, several new medications have been approved for use in horses to treat navicular syndrome. Most notably are the bisphosphonate drugs, Tildren and Osphos. The thought behind the use of these medications is to alter bone production and destruction by decreasing osteoclastic activity and increasing osteoblastic activity.

Osteoclasts are bone-resorbing cells, while osteoblasts are bone-forming cells. These medications help slow down the destruction and promote the production of bone. These drugs have been used in humans for years to treat osteoporosis,

severe arthritis and bone pain.

In the navicular syndrome patient, these drugs are used when lesions are found in the navicular bone itself, not in soft-tissue structures. Tildren is given slowly intravenously and has shown success when used for navicular syndrome, osteoarthritis and back pain, while Osphos is given intramuscularly in three different locations. Both drugs carry the potential of causing colic in the horse, but the episode is usually mild and transient. The bisphosphonates are increasing in popularity since being approved in the United States and are becoming the “go to” treatment for navicular cases with bone cysts and degenerative changes.

Injections

IF THE CONSERVATIVE APPROACH TO TREATING NAVICULAR SYNDROME with corrective shoeing and NSAIDS proves to be unsuccessful, injection with corticosteroids is usually the next step. Steroid injections can be performed via the coffin joint or navicular bursa. Typically the coffin joint is injected first, with the thought of reducing inflammation and synovitis. Communication between the coffin joint and navicular bursa allows corticosteroids injected into the coffin joint to medicate these structures.

When the lameness cannot be managed with coffin joint injections, the next step is injecting the navicular bursa itself. This is the space that surrounds and bathes the navicular bone with synovial fluid. The bursa is injected with a long needle through the back of the foot and delivers medication directly around the navicular bone. It carries a greater risk due to

injection through the deep digital flexor tendon.

Improvement in lameness is seen in 80 percent of horses that did not respond to conservative treatment. Injections are not a permanent fix and additional treatment modalities may be necessary.

Extracorporeal Shockwave Therapy

OVER THE PAST 15 YEARS, EXTRACORPOREAL SHOCKWAVE THERAPY has become increasingly more popular among veterinarians. It works by generating pressure waves in a fluid medium and is used for a wide variety of injuries including tendon and ligament tears, arthritis, back pain, navicular syndrome and a wide variety of other ailments.

The mechanism by which it works is still not completely understood, but it is capable of stimulating growth factors and inflammatory mediators, promoting new bone growth, developing new blood vessels, and providing localized pain relief, which can be a tremendous advantage in treating the navicular horse.

Surgery

SURGERY IS AN OPTION FOR THE HORSES THAT CONTINUE TO BE painful and maintain a significant degree of lameness, even after aggressive treatment.

The surgery – called a neurectomy – is also referred to as “nerving,” and is performed by removing the palmar digital nerve on the inside and outside of the lower leg. Removing the nerve provides pain relief to the back of the foot, including the navicular bone and surrounding structures. However, this is not a permanent fix, due to regrowth of the nerves. Soundness typically lasts from six months to three years.

Careful consideration should be made when choosing to perform a neurectomy due to the potential for complications post surgery. These complications include neuroma formation, rupture of the deep digital flexor tendon, fracture of the navicular bone, undetected abscesses and undetected penetration by a foreign body.

For these reasons, it is important to clean out and assess the patient’s foot daily after a neurectomy. Additionally, the suitability of the rider should be considered as well. Many vets would be hesitant to perform a neurectomy on a child’s horse, due to the risk of stumbling and falling following surgery. Despite the potential risks associated with nerving, it should be considered a viable option for the end-stage, refractory navicular horse.

There are numerous options for the treatment of navicular syndrome, with newer therapies being approved each year. The key to management of the navicular patient is balance. The hoof should be appropriately balanced when doing corrective shoeing. A balanced approach to pain management, rest and athletic performance should be considered. A balance of risk vs. reward should be considered when pursuing invasive treatments. The relationship between owner, veterinarian and farrier requires all parties to be on the same page and a balance of teamwork. This balance can yield a successful outcome with the navicular patient. ■



A diagnostic posterior digital nerve block will help determine if the horse's pain is coming from the heel/navicular area.

COURTESY OF AVS EQUINE HOSPITAL

Dr. Patrick First is an associate veterinarian at AVS Equine Hospital in Tallahassee, Florida. Dr. Patrick First, Dr. Steve Fisch, and Dr. Chad Baumwart operate a full-service equine referral hospital and reproductive center. If you have any questions, Dr. First can be reached at pfirstdvm@avsequinehospital.com.